

ORIGINAL ARTICLE

Medicine Science 2022;11(2):465-70

Evaluation of the effects of curcumin, erdosteine, vitamin E and vitamin C on paracetamol toxicity** Nursah Basol¹,  Cansel Ozmen²,  Seda Ocakli³,  Selcuk Cetin⁴**¹Tokat Gaziosmanpasa University, Faculty of Medicine, Department of Emergency Medicine, Tokat, Turkey²Tokat Gaziosmanpasa University, Faculty of Medicine, Department of Biochemistry, Tokat, Turkey³Tokat Gaziosmanpasa University, Faculty of Medicine, Department of Histology and Embryology, Tokat, Turkey⁴Tokat Gaziosmanpasa University, Faculty of Medicine, Department of Forensic Medicine, Tokat, Turkey

Received 23 August 2021; Accepted 16 December 2021

Available online 16.03.2022 with doi: 10.5455/medscience.2021.08.269

Copyright@Author(s) - Available online at www.medicinescience.org

Content of this journal is licensed under a Creative Commons Attribution-NonCommercial 4.0 International License.

**Abstract**

Paracetamol toxicity is one of the most common causes of drug induced toxicity in the world. This study aims to investigate the efficacy of curcumin, erdosteine, vitamin E and vitamin C administration in paracetamol-induced liver damage in comparison with N-acetyl cysteine (NAC) in the treatment and prevention of liver toxicity due to paracetamol poisoning. 49 Wistar-Albino rats were used for this study. The rats were randomly divided into 7 groups. Group 1, which was the control group, received no drug administration. All the other groups received the minimum toxic dosage of paracetamol (1 gr/kg). Group 2 was not administered any other drug. Curcumin (100 mg/kg) was administered to Group 3. Group 4 received Vitamin E (170 mg/kg) and Group 5 received Vitamin C (300 mg/kg). Erdosteine (150 mg/kg) was administered to Group 6 and the last group (group 7) was received NAC for 2 days. After 72 hours, the experiment was completed. Liver and kidney tissues and blood samples were collected. AST and ALT values were higher in PCT group compared with the control group. Additionally, in PCT group, SOD and GSH-PX levels were lower while MDA levels were found to be higher in comparison to the control group. In the treatment groups, curcumin proved to be the most efficient agent, with NAC and erdosteine following. Histopathological images supported that curcumin played a key role in preventing liver damage. On the other hand, the results indicated no significant contribution of vitamin E and C in reducing paracetamol induced liver damage. In the light of the results, it is indicated that oxidative stress and lipid peroxidation are principal mechanisms of paracetamol induced liver damage, whereas curcumin and erdosteine are efficient agents in preventing said damage. Furthermore, the findings of the study suggest that curcumin in particular can be used as an alternative drug to NAC after further research on humans.

Keywords: Paracetamol, toxicity, curcumin, liver**Introduction**

Paracetamol or acetaminophen is a widely used analgesic and antipyretic across the globe. In medicine it was first used in 1893, however its use gained popularity only after 1949. The fact that paracetamol, which can be sold with and without a prescription, is easily available and cheap plays a main role in its preferability [1]. Paracetamol has a high safety profile when used in therapeutic

doses, however it may cause severe hepatotoxicity when this dosage is exceeded. Paracetamol toxicity is the most common cause of acute liver failure in the USA and England [2,3].

Poisoning is commonly encountered in emergency services. In a study conducted in Turkey, it was determined that 59.6% of patients admitted to emergency rooms had drug poisoning, and 43% of them occurred due to pain medications [4]. Paracetamol is used in a wide range of symptoms: e.g. headache, toothache, neuralgias, migraine, menstrual pains, pain due to cold and flu infections, muscle and joint pain, pain due to surgical operations or injuries. It ranks high in analgesic poisoning due to its low price and availability as it can be sold without a prescription [5].

*Corresponding Author: Selcuk Cetin, Tokat Gaziosmanpasa University, Faculty of Medicine, Department of Forensic Medicine, Tokat, Turkey
E-mail: dr.scetin84@gmail.com

Paracetamol poisoning can occur acutely when taking more than 140 mg / kg or more than 7.5 grams in a 24-hour period in adults.

It may result in serious hepatic necrosis and death. Paracetamol, which has a dose-dependent toxicity, can cause kidney failure as well as liver failure [6].

After oral ingestion, paracetamol is metabolized in the liver by the cytochrome p450 enzyme system (CYPs) to its toxic metabolite N-acetyl-p-benzoquinonimine (NAB). This metabolite is detoxified by endogenous glutathione and excreted through the kidneys when normal doses of paracetamol are consumed. In high dose in-take, glutathione stores are depleted and as a result NAB cannot be detoxified leading to oxidative stress affiliated liver toxicity [7].

Curcumin is an important antioxidant obtained from the yellow flowered and large-leaved *Curcuma longa* plant belonging to the Zingiberaceae family which is widely grown in China and India. Curcumin is a potent hydroxyl radical scavenger and it traps superoxide radicals. Therefore, it protects DNA from oxidative damage [12]. In the literature, curcumin's anti-oxidant, anti-tumor, anti-inflammatory, anti-carcinogenic, anti-allergic, anti-dementia and free radical scavenger effects have been shown in many studies. In addition, curcumin is believed to be a powerful agent against diseases such as anorexia, diabetes, liver diseases, rheumatism, Alzheimer's, bile related disorders, and sinusitis [12,13].

Vitamins C and E, similar to curcumin, are also potent antioxidants. Vitamin C reacts with superoxides, hydroxyl radicals and singlet oxygens, rendering them ineffective. It also protects membranes against oxidant damage by destroying radicals that initiate lipid peroxidation. Vitamin E is a fat-soluble vitamin that consists of 8 tocopherols in nature. Among these 8 tocopherols, alpha-tocopherol is the most active and abundant in nature. Vitamin E, an essential antioxidant for biological systems, is found in membrane-rich tissues in particular. It prevents cell damage by breaking the lipid peroxidation chain, and helps maintain the normal intracellular signal transmission [13].

N-acetyl cysteine (NAC), which is the precursor of cysteine, is used orally or intravenously in the treatment of paracetamol intoxications. Erdosteine (N-carboxymethylthioacetyl-homocysteine thiolactone), similar to NAC, is a mucolytic and anti-oxidant drug. It has been developed for the treatment of chronic pulmonary diseases. Two sulfhydryl groups which can be released through liver metabolism play a role in the scavenging and antioxidant mechanism of erdosteine. There are studies in the literature showing the antioxidant effects of erdosteine [14,15].

Many studies have revealed that oxidant parameters increase and antioxidant parameters decrease due to oxidative damage that develops after paracetamol intoxication. In the present study, curcumin, vitamins C and E and erdosteine, which all have anti-oxidant properties, were administered to paracetamol toxicity induced rats to evaluate whether they have preventive effects primarily against liver and kidney failure. It was aimed to present a more accessible and efficient treatment protocol to the literature, as an alternative to NAC.

Materials and Methods

Group 1, which was the control group, received no drug administration. All the other groups received the minimum toxic dosage of paracetamol (1 gr/kg). Group 2 was not administered

any other drug. Curcumin (100 mg/kg) was administered to Group 3. Group 4 received Vitamin E (170 mg/kg) and Group 5 received Vitamin C (300 mg/kg). Erdosteine (150 mg/kg) was administered to Group 6 and the last group (group 7) was received NAC for 2 days. After 72 hours, the experiment was completed. Liver and kidney tissues and blood samples were collected.

Experimental Procedure

In the study, 49 Wistar-Albino rats weighing 200-220 g were used. Rat Group 1, which was the control group, received no drug administration. s were kept in light / dark with 12 hour periods and at 22-24 °C room temperature. Sufficient amount of drinking water and standard rat feed was supplied. Rats were randomly divided into seven groups. Group 1 (n=7), which was the designated control group, received no drug administration. The minimum toxic dosage of paracetamol (1 gr/kg) was administered to all the other groups through gavage method and the toxicity model was formed. Group 2 was not administered any other drug. Group 3 rats received paracetamol followed by curcumin (100mg/kg) at the 2nd hour. Afterwards, it was administered in doses of 100mg/kg/day. Group 4 rats received paracetamol followed by vitamin E (170mg/kg) at the 2nd hour by gavage method. It was continued as 170mg/kg/day. Group 5 rats received vitamin C 2 hours after the paracetamol administration in doses of 300 mg./kg/day for the 3 following days. Group 6 rats were administered paracetamol followed by erdosteine (150mg/kg) at the 2nd hour and then in 150 mg/kg/day doses. Group 7 received N-Acetyl Cysteine (NAC) at 150 mg/kg dosage 2 hours after the paracetamol administration. Afterwards, NAC was given at intervals of 4 hours at 70 mg./kg.

The experiment was completed 72 hours after the onset and anesthesia was provided intraperitoneally with ketamine 80 mg/kg and xylazine 10 mg/kg before termination. 4-6 mL blood sample was taken from the aorta with a sterile injector. Blood samples were centrifuged at 5.000 rpm for 5 minutes and serum was separated.

Study Groups

GROUP 1: Control group, n=7 (Control)

GROUP 2: 1g/kg dose (toxic dose) oral paracetamol (n=7) (PCT)

GROUP 3: 100mg/kg/day curcumin at the 2nd hour following a toxic dose of paracetamol and oral curcumin once a day for 3 days (n=7) (PCT+CUR)

GROUP 4: 170mg/kg/day vitamin E at the 2nd hour following a toxic dose of paracetamol. This practice was continued for 3 days. (n=7) (PCT+EVIT)

GROUP 5: 300mg/kg/day vitamin C at the 2nd hour following a toxic dose of paracetamol. This practice was continued for 3 days. (n=7) (PCT+CVIT)

GROUP 6: Erdosteine at the 2nd hour following a toxic dose of paracetamol (150 mg/kg loading dose, then 150 mg/kg once a day for 3 days). (n=7) (PCT+ERDO)

GROUP 7: NAC at the 2nd hour following a toxic dose of paracetamol (150 mg / kg loading dose, 70 mg/kg 17 times at 4 hour intervals). (n=7) (PCT+NAC)

Histopathological Examination

At the end of the study, an incision was made in the midline of the abdomen, and the right liver lobe and kidney were resected for histological examination. The kidney and liver tissues were fixed with 10% formalin before undergoing routine histological follow-up series and were afterwards embedded in paraffin blocks. 5 µm thick sections from the paraffin blocks were placed on polylyzed slides. Hematoxylin-eosin staining was performed on the samples before they were examined under Olympus BX50 type binocular microscope in order to detect any histopathological differences between the groups. Liver and kidney tissues were examined in terms of connective tissue growth, granular degeneration, mononuclear cell infiltration, necrotic cells and vascular congestion. A scoring was established according to the damage that occurred in the liver tissues. In line with this; 0-20% hepatocyte damage was determined as grade 1, 20-40% hepatocyte damage as grade 2, 40-60% hepatocyte damage as grade 3, 60-80% hepatocyte damage as grade 4 and, 80-100% hepatocyte damage as grade 5.

Biochemical Examination

Biochemical parameters reflecting liver function (AST, ALT, Total Bilirubin (T.Bil.), Direct Bilirubin (D.Bil)) and renal function (BUN, Creatine (Cre)) were measured via an autoanalyzer (Konelab 60 i®) using the serum samples delivered to the Biochemistry Department laboratory in the same day. Superoxide dismutase (SOD), Glutathione peroxidase (GSH-Px) activities and MDA levels of tissues were measured spectrophotometrically (Schimadzu, UV 1601). AST, ALT, BUN, Cre, T.Bil, and D.Bil. enzymes were studied in an autoanalyzer (Roche Modular P 800).

Statistical Analysis

All statistical analyzes were performed using the SPSS (Statistical Package for Social Sciences) 15.0 statistical program. Data were presented as mean±standard deviation (mean±SD). The significance of the differences between groups was determined by the Mann-Whitney U test and Kruskal Wallis analysis. $p<0.05$ was considered statistically significant.

Results

A total of 49 rats were used during the study. No adverse events or unexpected effects related to the application were observed in any subject. The biochemical parameters following the blood test and their statistical analysis are presented in table 1 (Table 1). Accordingly, there was a statistically significant difference in AST and ALT values between the control group and the PCT group, i.e. the toxicity group ($p<0.05$). AST and ALT values were higher in the toxicity group (PCT group) in comparison to the other groups. When the treatment groups were evaluated, it was found that AST and ALT were the lowest in the curcumin administered group (PCT+CUR), with a statistically significant difference; followed by the NAC (PCT+NAC) and erdosteine (PCT+ERDO) groups, respectively. Furthermore, the rats were evaluated in terms of kidney functions; although BUN and creatine values had increased, there was no statistically difference compared with the control group. This result suggested that the renal damage had not occurred adequately in the created toxicity model. In parallel with this, the treatment groups presented no significant differences regarding BUN and creatine values.

MDA, SOD and GSH-PX values obtained from the resected liver tissues are shown in Table 2 (Table 2). Accordingly, in the toxicity group (PCT group); the MDA value was higher, whereas the SOD and GSH-PX values were lower in comparison to the control group and these differences were statistically significant ($p<0.05$).

Histopathological evaluations of the liver tissue samples were performed (Figure 1). In view of this, diffuse centrilobular hepatocyte necrosis and vacuolar degeneration were observed in the PCT group, in contrast to the control group. When the groups were compared regarding their degrees of hepatocyte damage, it was found that the PCT group presented the highest damage with a statistically significant difference in comparison to the control group ($p<0.001$). Furthermore, the histopathological examination findings indicated a statistically significant difference in the degrees of damage detected between the PCT group and the curcumin, erdosteine and NAC groups ($p<0.01$) (Table 3).

Table 1. Biochemical Parameters of the Groups

	CONTROL Mean±SD	PCT	PCT+CUR	PCT+EVIT	PCT+CVIT	PCT+ERDO	PCT+NAC
AST	45.7±2.5	537±23.8 *	182±14.7#	451±21.7	468±14.8	255±15.7#	223.8±14.9#
ALT	65.5±3.4	144.6±14.5 *	52.6±8.6 #	115.2±17.4	118.3±12	80.2±13.1 #	78.8±20.1 #
T.BIL	0.115±0.14	0.136±0.07	0.196±0.16	0.21±0.28	0.186±0.36	0.17±0.09	0.11±0.15
D.BIL	0.03±0.01	0.036±0.02	0.035±0.01	0.048±0.023	0.04±0.014	0.045±0.016	0.042±0.013
BUN	16.5±5.6	26±3.4	24.3±5.7	21.6±8.4	26±4.3	19.5±7.9	24±6.2
CRE	0.51±0.2	0.7±0.4	0.6±0.1	0.56±0.2	0.6±0.1	0.625±0.2	0.58±0.3
CRP	0.2±0.02	0.2±0.04	0.2±0.01	0.14±0.01	0.16±0.02	0.175±0.03	0.18±0.01

*= $p<0.05$ (CONTROL and PCT)

#= $p<0.05$ (PCT and PCT+CUR, PCT+ERDO, PCT+NAC)

Table 2. MDA, SOD and GSH-PX values in liver tissues of the groups

	CONTROL Mean±SD	PCT	PCT+CUR	PCT+EVIT	PCT+CVIT	PCT+ERDO	PCT+NAC
MDA (nmol/g protein)	0.608*	2.771*	0.945	1.538	1.701	0.987	1.265
SOD (U/mg protein)	0.157 *	0.011 *	0.043	0.081	0.032	0.155	0.092
GSH-PX (U/g protein)	2.138 *	0.047*	0.945	1.451	1.128	0.637	0.948

* p<0.05 (between the Control and PCT group)

Table 3. Valuation of the degree of liver damage in the groups

Groups	Degree of Damage
CONTROL	0.3±0.2
PCT	4.8±0.2 *
PCT+NAC	1.5±0.3 #
PCT+ERDO	1.8±0.3 #
PCT+ EVIT	4.5±0.4
PCT+CUR	1.3±0.2 #
PCT+CVIT	4.6±0.1

* p < 0.001 (Control group and PCT group)
p < 0.01 (PCT group and the treatment groups)

Discussion

In the present study, a significant difference was found in the AST and ALT values between the toxicity group and the control group. Thus, indicating that liver damage occurred in the experimental poisoning model. Liver damage is an expected outcome of paracetamol toxicity when toxic doses are reached. A high portion of paracetamol is metabolized in the liver [16]. It is inactivated into sulfate and glucuronide conjugates if consumed in therapeutic dosage (partially by the effect of cytochrome P450). However, intermediate metabolites with a toxicity of about 8% are also formed. These metabolites are reduced by glutathione in the liver and eliminated from the urine in the form of cysteine and mercapturic acid conjugates. When paracetamol is consumed in toxic doses, these metabolites overload and the glutathione stores of the liver begin to drain rapidly. In addition to this, they bound with macromolecules that form hepatocyte necrosis resulting in liver necrosis. The severity of liver necrosis depends on the glutathione stores, and the activity of cytochrome P450 and glucuronization systems. The toxic and electrophilic metabolites of paracetamol are normally conjugated with hepatic glutathione, however due to depleted glutathione stores liver necrosis occurs. In chronic alcoholics and abusers of drugs which affect the liver microsomal system (diphenylhydantoin, phenobarbital, valproic acid), toxic metabolites will accumulate causing a higher sensitivity to paracetamol toxicity [17-20]. Similar mechanisms are also observed in kidney tissues, however since only 5% is metabolized by the kidneys, liver damage is more prominent in clinical practice [21,22].

When the levels of SOD, GSH-PX and MDA in the liver tissues are evaluated, the low SOD and GSH-PX and high MDA provides insight over the mechanism. In view of this, it can be said that, although not alone, the increase in oxidation and lipid peroxidation is effective in the course of liver damage due to paracetamol poisoning. SOD and GSH-PX are two main enzymes of the antioxidant system. SOD converts superoxide radicals into hydrogen peroxide, the substrate of GSH-PX, while GSH-PX catalyzes the conversion of hydrogen peroxide to water. However, the role of these enzymes in drug toxicity due to paracetamol is controversial [23,24]. In recent years, there have been increasing studies on the protective effects of antioxidant enzymes in paracetamol toxicity. Studies have indicated a resistance to hepatic damage in the absence of SOD and GSH-PX [25,26]. Cheng et al., stated that SOD and GSH-PX decreased in paracetamol poisoning, which is parallel with the results of the present study [27]. In other words, the results suggest that oxidative stress plays a role in paracetamol

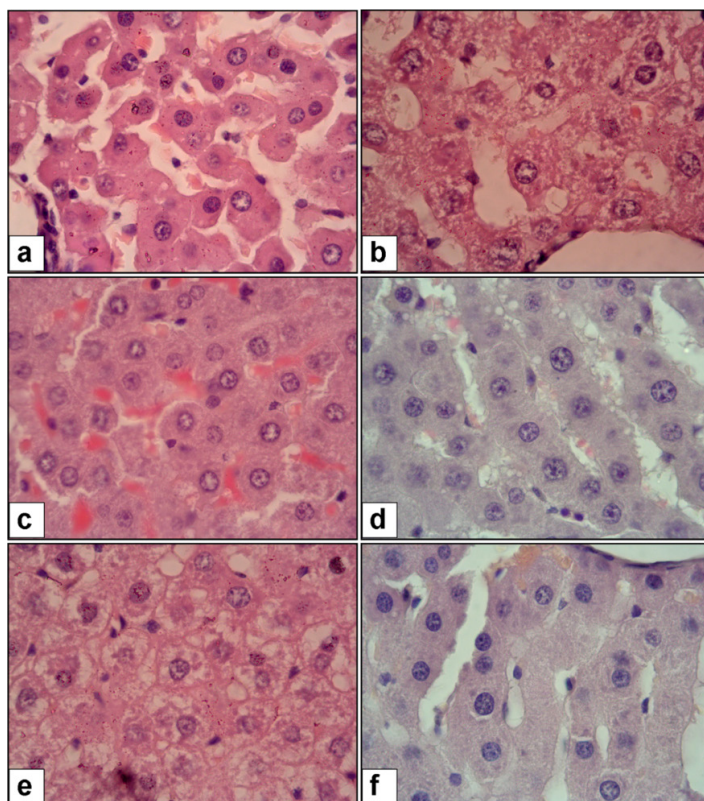


Figure 1. Liver histopathology Hematoxylin - eosin stain. Liver zone 3 sites (periphery of vena centralis) H&E (40X100). a) CONTROL group, b) PCT Group, c) PCT+NAC Group, d) PCT+ERDO Group, e) PCT+EVIT Group, f) PCT+CUR Group

toxicity. MDA, which is an indicator of lipid peroxidation, was found to be high in the experimental toxicity model. Similar to the results of the current study, Farag et al. presented high levels of MDA in the paracetamol poisoning induced rat model [28]. These findings indicate that, lipid peroxidation may be a determinant in the mechanism of toxicity and liver damage [29].

In the present study, regarding renal damage, there was an increase in the levels of BUN and creatinine in the toxicity group, however this difference was not statistically significant. This finding indicates that kidney damage did not sufficiently develop in the toxicity group. As mentioned previously, this is an expected result considering the low metabolism level of paracetamol from the kidneys [21]. Consequently, studies in the literature mainly focus on evaluating the liver damage due to paracetamol.

NAC therapy is used to prevent or reduce the toxic effects of paracetamol on the liver. NAC, a glutathione and sulfate precursor, is the most frequently studied and administered antidote. It is metabolized to cysteine in the cell. These two properties of NAC have made it the essential agent it is today [30]. However, the high risk of developing allergies, particularly in its intravenous form, led to the search for alternative treatment modalities to NAC therapy. In the present study, the efficiency of NAC in correcting liver damage caused by paracetamol has been demonstrated through both biochemical and histopathological approaches. Nevertheless, curcumin was found to be more effective in comparison to NAC following the evaluation of the findings. Erdosteine has been found to be similarly effective. The vitamin E and C administrations, on the other hand, did not present any beneficial effects. These findings are consistent with the literature [31,32]. When evaluated in terms of possible mechanisms, it can be said as a result of the results of this study that oxidative stress and lipid peroxidation are effective in terms of liver toxicity. However, when viewed in terms of treatment protocols, SOD, MDA and GSH-PX do not have a statistically significant difference, therefore a definite conclusion cannot be drawn on this issue. The mechanism by which curcumin and erdosteine act in reducing the liver necrosis caused by paracetamol is yet to be clarified.

Conclusion

In this study, NAC, erdosteine and curcumin treatments were shown to be effective in liver damage caused by paracetamol toxicity. Although NAC is the most commonly used antidote, curcumin in particular may be considered as an alternative in the treatment course. After large-scale human studies are conducted on this subject, Curcumin can become a treatment option especially in cases of NAC allergy.

Conflict of interests

The authors declare that they have no competing interests.

Financial Disclosure

All authors declare no financial support.

Ethical approval

T.R. Gaziosmanpaşa University Rectorate Animal Experiments Local Ethics Committee permission letter dated 01.09.2014 and numbered 51879863-238, project number HADYEK-38.

References

- Guggenheimer J, Moore PA. The therapeutic applications of and risks associated with acetaminophen use: a review and update. *J Am Dent Assoc.* 2011;142:38-44.
- Lee WM. Acetaminophen toxicity: Changing Perceptions on a Social/Medical Issue. *Hepatology.* 2007;46:966-70.
- Larson AM, Polson J, Fontana RJ, et al. Acetaminophen-induced acute liver failure: results of a United States multicenter, prospective study. *Hepatology.* 2005;42:1364-72.
- Akkose S, Bulut M, Armagan E, et al. Acute poisoning in adults in the years 1996-2001 treated in the Uludag University Hospital, Marmara Region, Turkey. *Clinical Toxicology (Phila).* 2005;43:105-9.
- Burke A, Smyth EM, Fitzgerald GA. Analgesic-antipyretic agents: pharmacotherapy of gout. In: Brunton LL, Lazo JS, Parker K, eds, Goodman and Gilman's the Pharmacological Basis of Therapeutics. 11th edition. McGraw-Hill, New York, 2006; 671-716.
- Makin AJ, Williams R. Acetaminophen-induced hepatotoxicity: predisposing factors and treatments. *Advances Int Med.* 1997;42:453-83.
- Schilling A, Corey R, Leonard M, Eghtesad B. Acetaminophen: old drug, new warnings. *Cleveland Clin J Med.* 2010;77:19-27.
- Larson AM. Acetaminophen hepatotoxicity. *Clinics in liver disease.* 2007;11:525-48.
- Brok J, Buckley N, Gluud C. Interventions for paracetamol (acetaminophen) overdose. *Cochrane Database of Systematic Reviews.* 2006;CD003328.
- Waring WS, Jamie H, Leggett GE. Delayed onset of acute renal failure after significant paracetamol overdose: a case series. *Hum Exp Toxicol.* 2010;29:63-8.
- Mercan U. Importance of Free Radicals in Toxicology. *Van Vet. J.* 2004;15:91-6.
- Piper JT, Singhal SS, Salameh M, et al. Mechanisms of anticarcinogenic properties of curcumin: the effect of curcumin on glutathione linked detoxification enzymes in rat liver. *Int J Biochem Cell Biol.* 30; 445-56.
- Akpolat M, Topçu Y, Kanter M. Investigation Protective Effects of Curcumin and Vitamin C on Ionizing Radiation-Induced Morphological Destruction of Intestinal Mucosa in Rats. *J Med Invest.* 2008;6:77-85.
- Baniasadi S, Eftekhari P, Tabarsi P, et al. Protective effect of N-acetylcysteine on antituberculosis drug-induced hepatotoxicity. *Eur J Gastroenterol Hepatol.* 2010;22:1235-8.
- Dechant KL, Noble S. Erdosteine. *Drugs.* 1996;52:875-81.
- Dökmenci İ. Farmakoloji Temel Kavramlar (Pharmacology Basic Concepts). Nobel Tıp Kitabevi, İstanbul, 2000;406:153-9.
- Kayaalp SO. Rasyonel Tedavi Yönünden Tıbbi Farmakoloji (Medical Pharmacology in terms of Rational Treatment). Hacettepe-Taş Kitapçılık Ltd.Şti, Ankara, 2005;125-9;848-50.
- Dworkin PD. NMS Pediatri (NMS Pediatrics), 3rd. edition. Nobel Tıp Kitabevi, İstanbul, 2000;53-7.
- Hinson JA. Reactive metabolites of phenacetin and acetaminophen. environmental health perspectives. University of Melbourne. Australia. 1983;49:71-9.
- Potter DW, Hinson JA. Mechanisms of Acetaminophen Oxidation to N-Acetyl- benzoquinone imine by horseradish peroxidase and cytochrome P-450. *The Journal of Biological Chemistry.* 1987;3:966-73.
- Ranganathan S, Sri, Sathiadhas MG, Sumanasena S, et al. Fulminant hepatic failure and paracetamol overuse with Therapeutic intent in febrile children. *The Indian Journal of Pediatrics.* 2006;73: 871-5.
- Lauterburg BH, Corcoran GB, Mitchell JR. Mechanism of Action of N-Acetylcysteine in the protection against the hepatotoxicity of acetaminophen in rats in vivo. *J Clin Invest.* 1983;71:980-91.
- James LP, Mayeux PR, Hinson JA. Acetaminophen-Induced Hepatotoxicity: Drug Metabolism and Disposition. 2003;31:1499-506.
- Lei XG, Zhu JH, McClung JP, et al. Mice deficient in Cu, Zn-superoxide dismutase are resistant to acetaminophen toxicity. *Biochem J.* 2006;399:455-61.

25. Kim SJ, Lee MY, Kwon DY, et al. Alteration in metabolism and toxicity of acetaminophen upon repeated administration in rats. *J Pharmacol Sci.* 2009;111:175-81.
26. Zhu JH, Zhang X, McClung JP, et al. Impact of cu, zn-superoxide dismutase and se-dependent glutathione peroxidase-1 knockouts on acetaminophen-induced cell death and related signaling in murine liver. *Exp Biol Med.* 2006;231:1726-32.
27. Cheng WH, Quimby FW, Lei XG. Impacts of glutathione peroxidase-1 knockout on the protection by injected selenium against the pro-oxidant-induced liver aponecrosis and signaling in selenium-deficient mice. *Free Radic Biol Med.* 2003;34:918-27.
28. Farag MM, Mohamed MB, Youssef EA. Assessment of hepatic function, oxidant/antioxidant status, and histopathological changes in rats treated with atorvastatin: Effect of dose and acute intoxication with acetaminophen. *Hum Exp Toxicol.* 2015;34:828-37.
29. Jaeschke H, Knight TR, Bajt ML. The role of oxidant stress and reactive nitrogen species in acetaminophen hepatotoxicity. *Toxicology Letters.* 2003;144:279-88.
30. Atkuri KR, Mantovani JJ, Herzenberg LA, et al. N-Acetylcysteine - a Safe antidote for cysteine/glutathione deficiency. *Current Opinion in Pharmacology.* 2007;7:355-9
31. Saritas A, Kandis H, Baltaci D, et al. N-Acetyl cysteine and erdosteine treatment in acetaminophen-induced liver damage. *Toxicol Ind Health.* 2014;30:670-8.
32. Li G, Chen JB, Wang C, et al. Curcumin protects against acetaminophen-induced apoptosis in hepatic injury. *World J Gastroenterol.* 2013;14:7440-6.